

Findings in the Live Blood Analysis of Patients after Covid Injections:

Metallic (or Other?) Objects and Granulocytes Attacking One Another

Doctors for Covid Ethics
Online Meeting
January 13th 2022

Eva-Maria Schottdorf

Outline

1. My cooperation with alternative practitioners
2. A few words about live blood analysis, LBA
3. The metallic (or other?) objects
4. The granulocytes attacking each other:
 - three cases so far, pictures of the first one
 - clinical findings, especially one of the three patients
 - consequences (patients, doctors' awareness, necessary measures)
 - What steps shall we, the D4CE, take?

Our Cooperation

So far, I work with two alternative practitioners

- very critical with their work (which findings are new?)

Why: Their pictures show important results which could help to stop the injections

Aim: Combining their findings with systematical analysis

type of injection, how many

dates of the injections


pat.: clinical condition, past medical history, medication, etc.

They both wish to remain anonymous

Live Blood Analysis, LBA

- one drop of blood is taken from the fingertip
- it falls directly onto the microscope slide
- a coverslip is placed on top
- the cells are still alive
- the sample is viewed against a dark background:
 - => the cells and objects appear in white

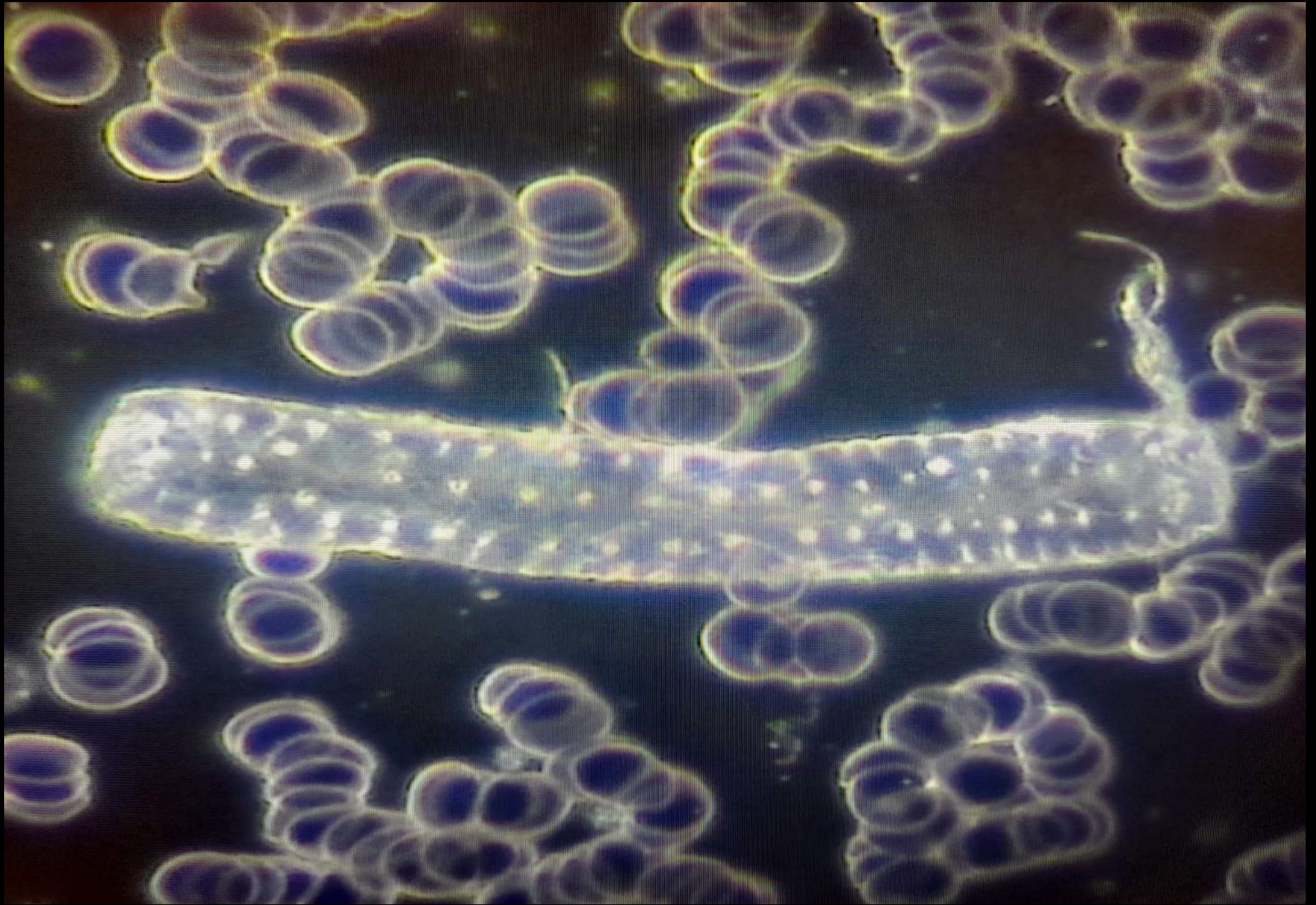
The Objects I



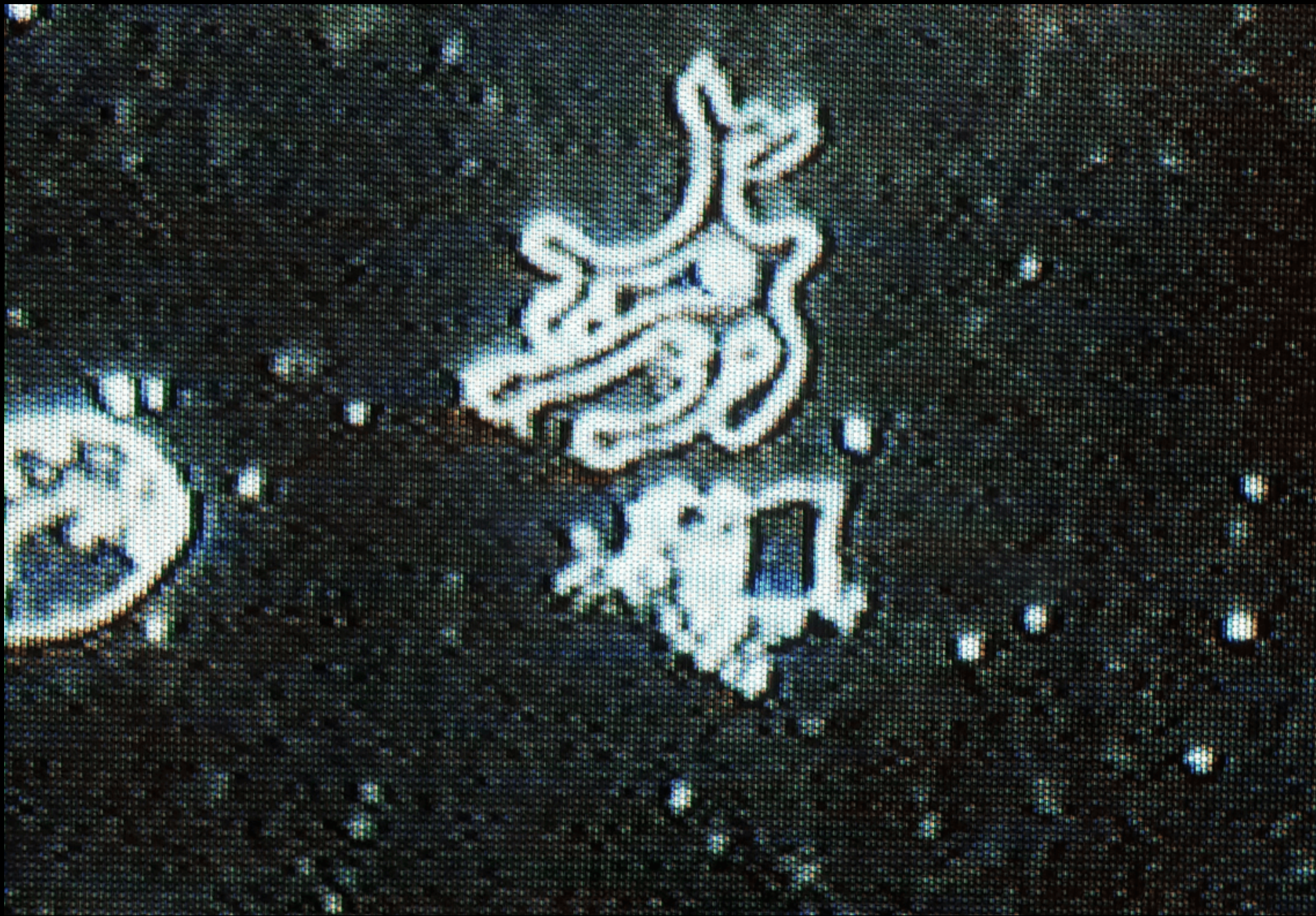
The Objects II - About the Patient

- 50 year old gentleman
- coronary arteries blocked after second injection (type?)
- 7-8 stents were inserted into the coronary arteries
- patient takes marcumar (equivalent to warfarin)
- after third injection the following object was found
- finding discussed with him in front of the monitor
- his comment: "Ok, so what is this?" (pointing towards another cell/usual finding on the monitor)

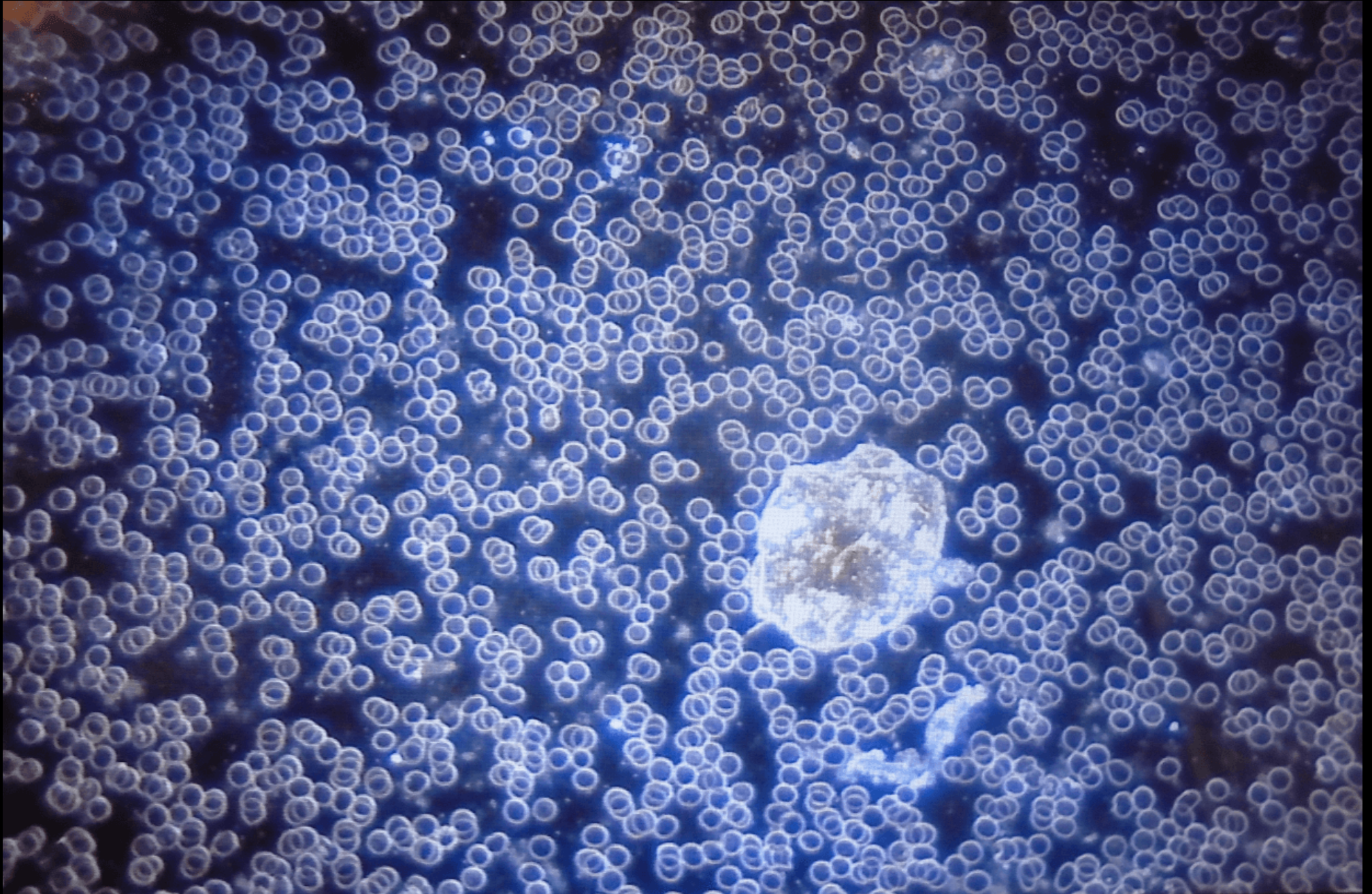
The Objects II -The Object Itself



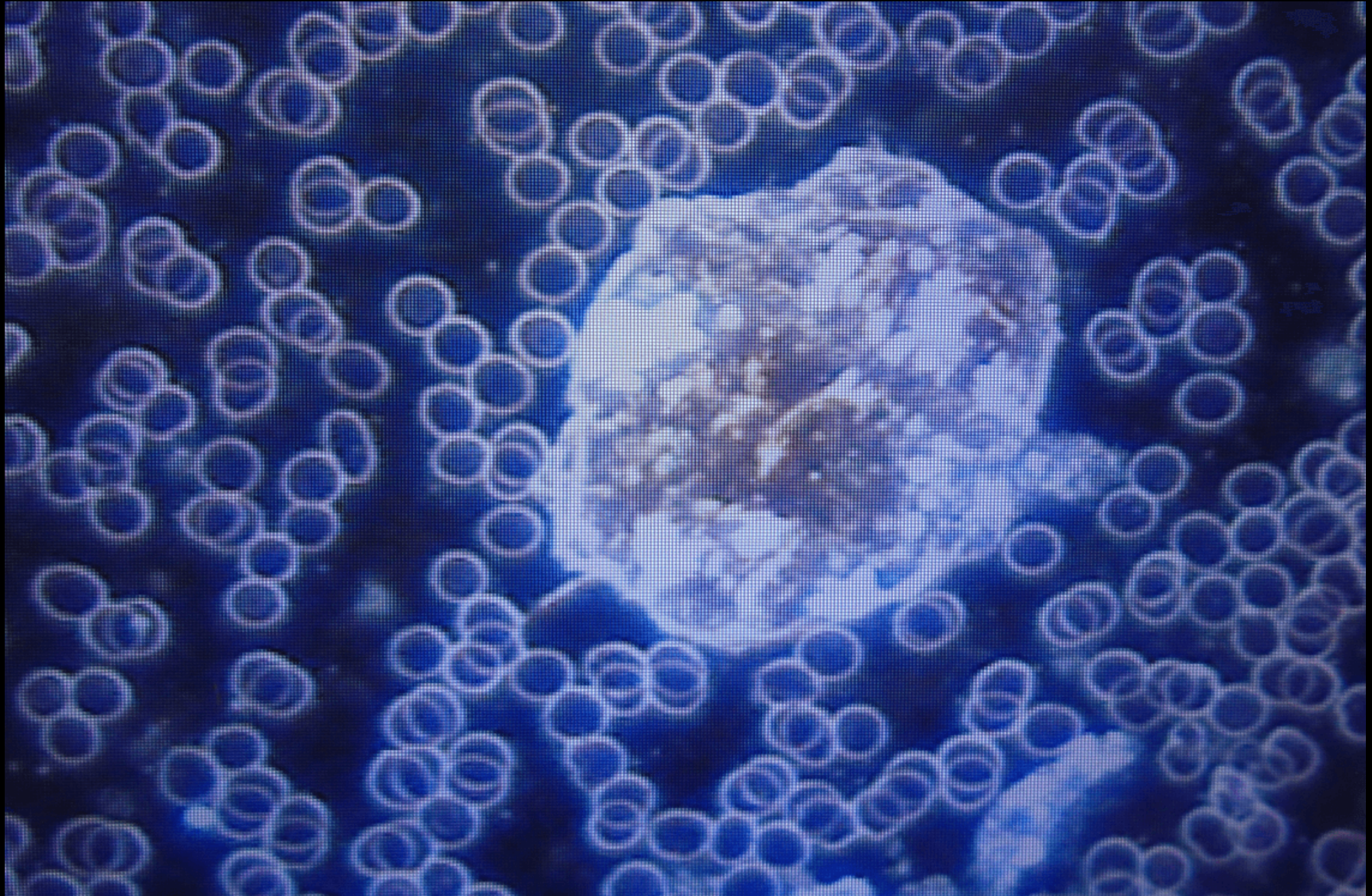
The Objects III



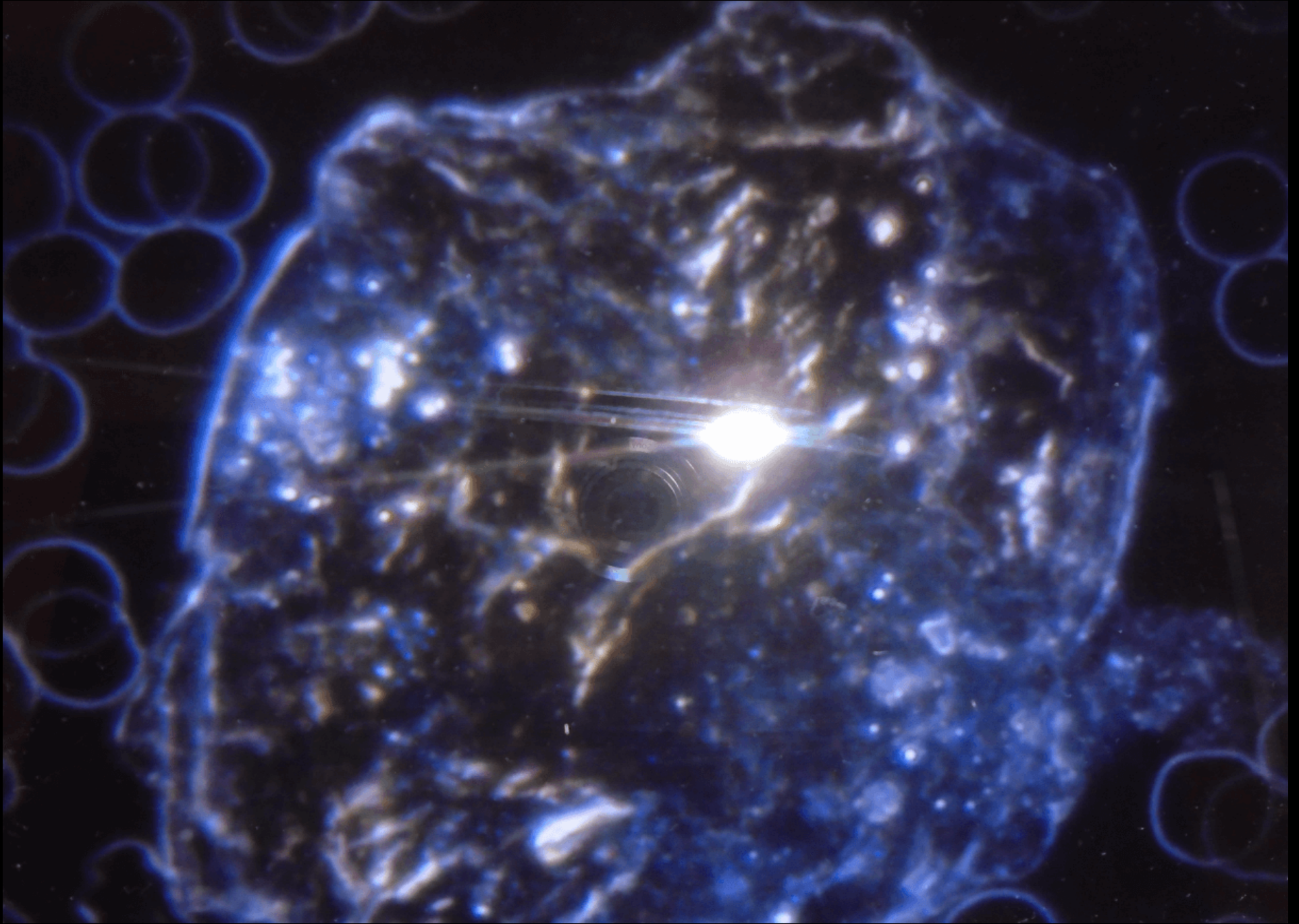
The Objects IV - First Magnification



The Objects IV - Second Magnification



The Objects IV - Third Magnification



What Are Granulocytes?

- granulocytes are white blood cells
- main task of the neutrophils (majority in the blood):
to incorporate bacteria and foreign material
 - => vital role in warding off bacterial infections
- other granulocytes incorporate parasites and play a role
in allergic reactions


About the First Patient

- 57 year old lady
- 3-4 days after her third injection
- type of injection not known
- reason for consultation: routine checkup
- clinical presentation:
 - the patient felt tired and did not mention specific symptoms

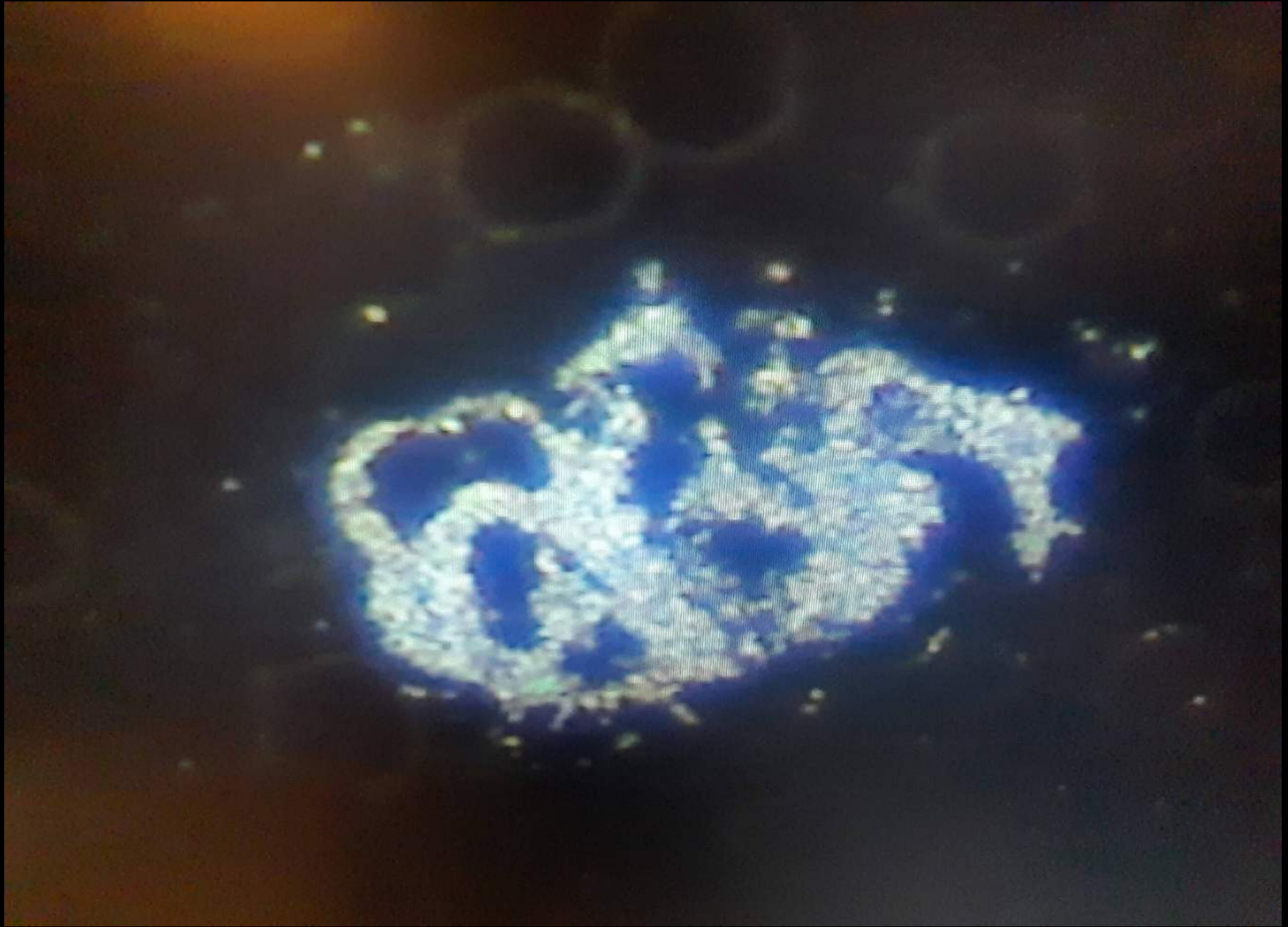What Did her Granulocytes Do?

- cells on the slide still alive
- the granulocytes swam towards one another
- they started attacking one another:
 - either, one completely engulfed the other
 - or both attacked the other one, finally lysing each other
- all granulocytes in the sample behaved that way

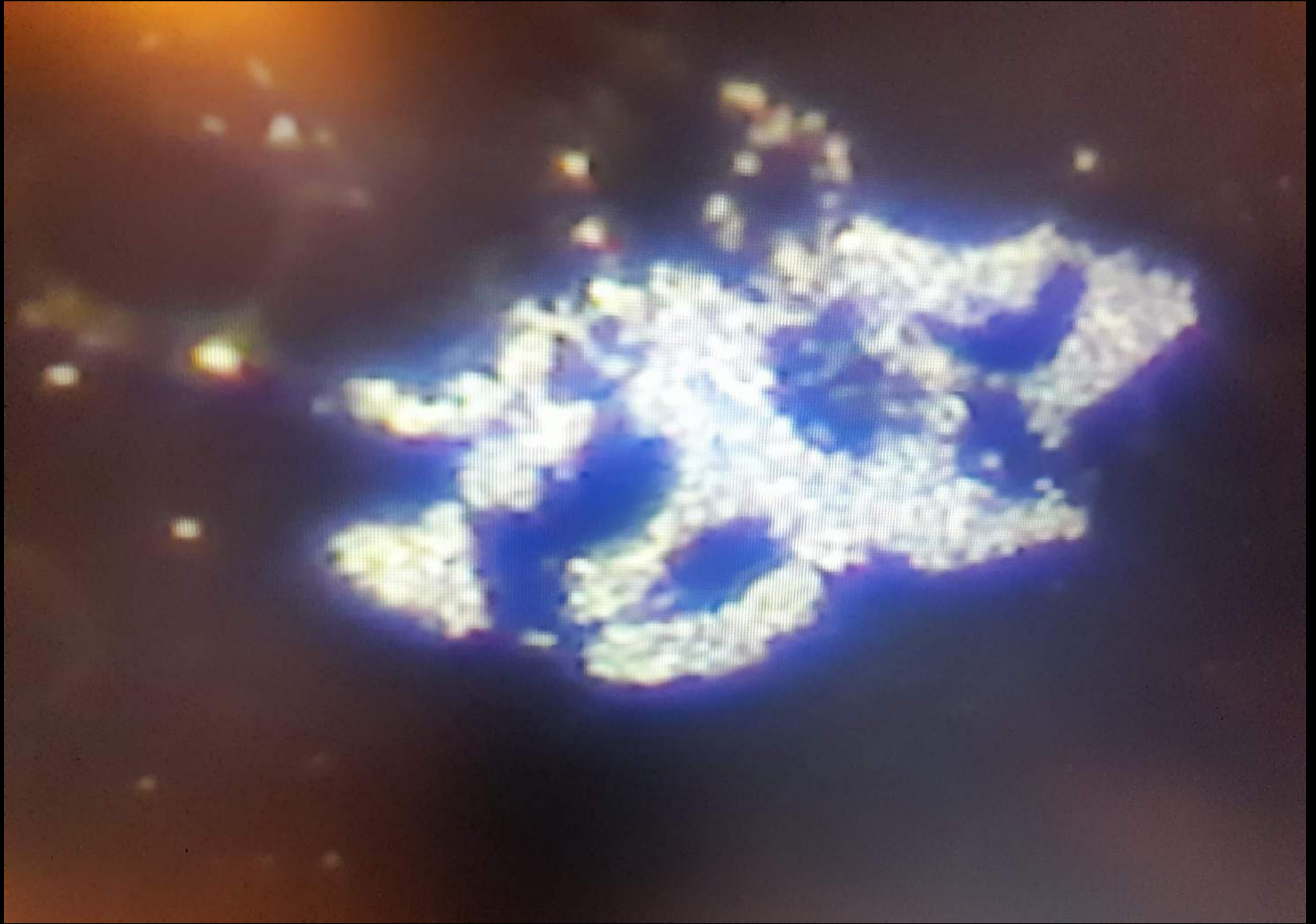The Granulocytes - First Pair



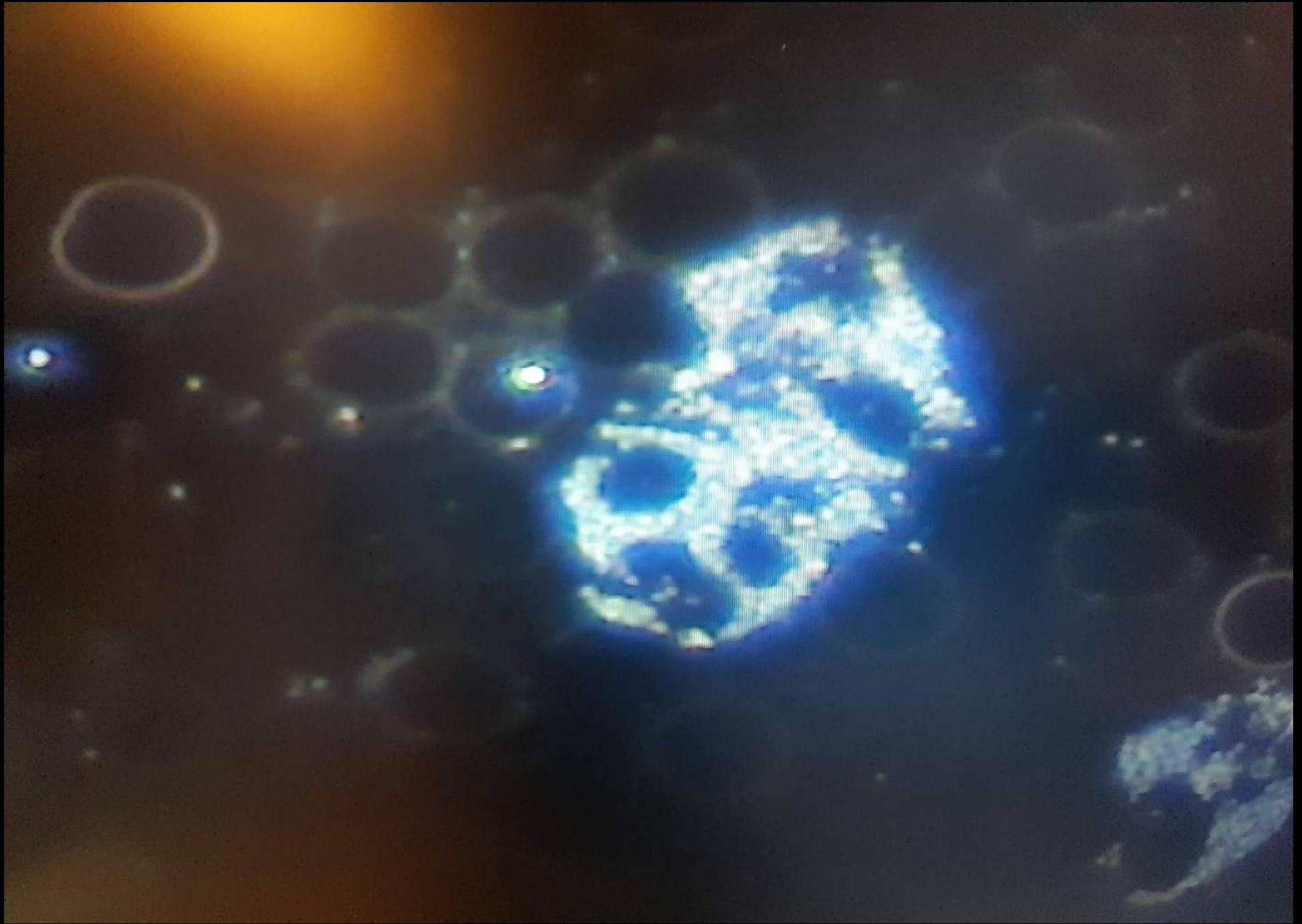
The Granulocytes - Second Pair



The Granulocytes - Third Pair



The Granulocytes - Fourth Pair



Second Patient with Selfattacking GC - I

- a gentleman, born 1947
- past medical history:
 - renal insufficiency
 - cardiac insufficiency
 - pulmonary hypertension
- third shot (type?) on December 16th 2021
- consultation with the expert on Monday, January 10th 2022
- his condition had deteriorated:
 - renal function worsened according to lab results
 - anemia (too few red blood cells), dyspnea

Second Patient with Selfattacking GC - II

- in hospital since January 11th, poor prognosis
- his live blood analysis showed the same results as we have just seen in the slides above
 - all granulocytes in pairs, busy eating up each other

Third Patient with Selfattacking GC

- a lady, born 1947, the above mentioned patient's wife
- also her third injection on December 16th 2021
- consultation together with her husband
- she felt unwell during the consultation, could not name any specific symptoms
- in the LBA, also all of her granulocytes had formed pairs and attacked one another

How to Proceed? - Asking Questions

Does this happen in the entire blood? For how long?

If so, what does the patients' white blood count look like?

How many patients do experience this?

Have there been more patients presenting with bacterial infections or even sepsis as usual?

How long does the generation of new granulocytes take?

Are they fulfilling their tasks properly?

What causes the granulocytes to behave like this?

How to Proceed? - Identifying Problems

Clearly:

The following could happen, no panic, but sensible actions necessary

Granulocytopenia:

If there patients develop serious granulocytopenia, they are left without their defense against bacteria and could develop infections, leading to sepsis/septic shock

Sepsis might be difficult to detect:

patients tend to develop a fever after the shots, as well as unspecific symptoms (differential diagnosis!) therefore, patients might not present to physicians

How to Proceed? - Proposed Steps

If an alternative practitioner encounters these granulocytes:

send the patient to a doctor/hospital immediately:
white blood count, other lab tests
thorough clinical examination, including swabs as necessary

Doctors (EMS, surgeries, hospitals):

be aware of that condition, inform/monitor patients
remember the golden hour of sepsis

We as D4CE:

Shall we formulate a statement to warn colleagues?
If so, put it on the website/send it to the chambers of physicians?